



Evaluation of Trabecular Metal Material Dental Implant Assembly in a Canine Periimplantitis Model

Suneel Battula, PhD, Jin Whan Lee, PhD, Savvas Papanicolaou, MS, Hai Bo Wen, PhD, Michael Collins, MS, MBA

Zimmer Dental Inc., Carlsbad, CA

Presented at the Academy of Osseointegration Annual Meeting, 2013

1 Background

Osseointegration (or bone ongrowth) was described by Brånemark et al, as the process of living bone forming structural and functional connection with a load carrying titanium implant.¹ Osseoincorporation is the combination of bone ingrowth and bone ongrowth which was demonstrated by a dental implant with Trabecular Metal™ material (TM),^{2,3} a cancellous-like osteoconductive structure with interconnected porosity. Prior studies conducted using a TM implant in a healed site canine model demonstrated active bone formation inside the pores at early healing stages and level of osseointegration and stability comparable to clinically successful conventional threaded implant.² The aim of the study was to evaluate the performance of a dental implant assembled with porous TM sleeve in an experimentally induced canine periimplantitis model by comparing with conventional titanium (Ti) threaded implant with respect to tissue response, histomorphometry and risk of infection.

2 Materials and Methods

Test (TM and Ti6Al4V) and control (Ti6Al4V) dental implants (4.1mm x13mm, n=32) were bilaterally placed in mandibular premolar and molar extraction sockets of eight hound dogs (4 test and 4 control implants per dog) by random assignment. The extraction sockets were filled with bone graft material (Puros® Cancellous Particulate). 12 weeks post implantation, periimplantitis was induced by placement of ligatures in periimplantitis (PI) group (4 dogs) while the sham group (4 dogs) received regular oral prophylaxis. The dogs in the PI group did not receive oral prophylaxis. The ligatures were placed in the cervical region of the implants and were held in place by a healing collar. Probing depth (PD) was measured for the 24 week group at 18 & 24 weeks and for the 38 week group at 18, 24, 30 & 38 weeks.

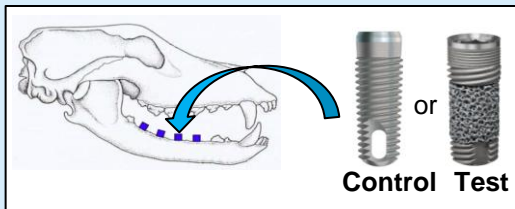


Figure 1: Implant placement in a canine model.

Four dogs were euthanized at 24 and 38 weeks after implantation. Histological sections (one section per dog) were obtained at necropsy at 24 & 38 weeks post implant placement (Figure 2) and were stained with Sanderson's rapid bone stain to assess percent bone-implant-contact (%BIC), amount of bone formed and histopathological parameters (acute and chronic inflammation, fibrosis, evidence of bacterial infection and soft tissue in contact with the implant). %BIC was measured along the entire length of the implant and total amount of bone formed was compared due to the differences in the geometries of the implants. Effects of implant type on the histomorphometric and histopathological parameters and probing depth were statistically analyzed.

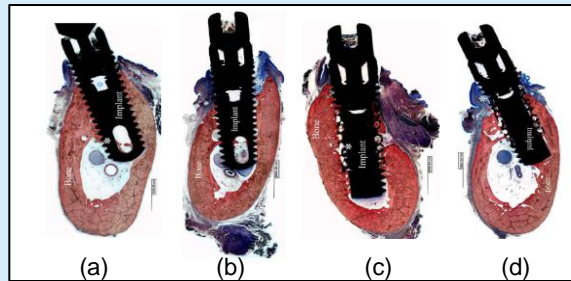


Figure 2. Histological sections of 38 weeks group (a) Control Sham (b) Control PI (c) Test Sham (d) Test PI

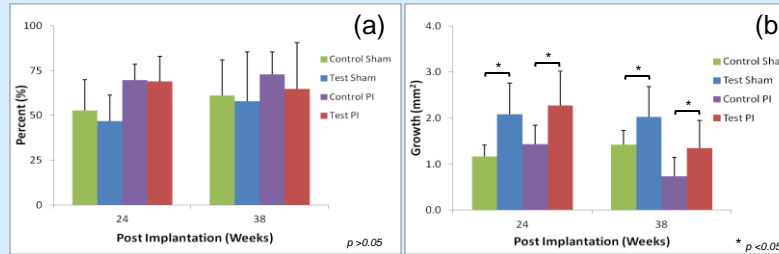


Figure 3. Comparing histomorphometric parameters measured for different implant systems (a) %BIC (b) total amount of bone formed.

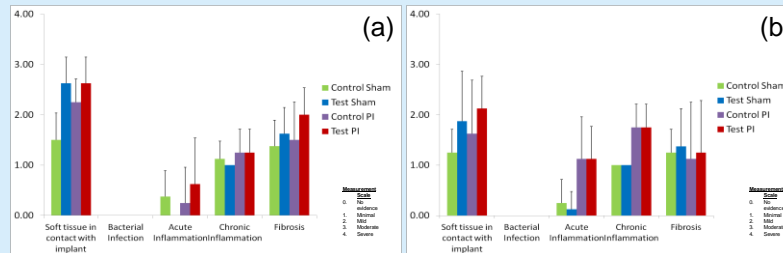


Figure 4. Comparing histopathological parameters measured for different implant systems at (a) 24 weeks (b) 38 weeks

3 Results

All implants survived, control implants showed osseointegration and test implants showed osseoincorporation clinically and histologically. All the implants in the PI group exhibited significant loss of supporting tissue with progression of periimplantitis but all the implants survived (Figure 2). PD of sham group for both types of implants was lower and statistically different from that of PI group for both 24 & 38 week groups. The PD at 18 and 24 weeks was significantly different from that at 30 & 38 weeks in the 38 week study group which indicated the progression of periimplantitis. The mean bone-implant-contact (BIC) values were 52.7% & 62.9%, 69.6% & 71.3%, 46.9% & 56.2%, 68.9% & 64.8% for control (sham & PI) and test (sham & PI) groups at 24 & 38 weeks respectively. BIC values showed no statistical difference between the groups for threaded Ti portions of the implants (Figure 3). More bone was found in area encompassing the threaded and porous regions along the length of the implant, for test implants in both the sham and PI groups. In the porous region, test implants demonstrated a mean bone ingrowth of 28.4% & 36.33% and 35.6% & 32.7% for sham & PI groups at 24 and 38 weeks respectively. Histopathological analysis (Figure 4) showed minimal to mild incidence of acute and chronic inflammation but did not reveal any evidence of bacterial infection within peri-implant tissues or inside TM pores in any of the groups. The analysis also indicated mild to minimal fibrosis and moderate to minimal soft tissue contact with the implant for both control and test dental implants.

4 Conclusion

The histopathological and histomorphometric findings from this canine study suggest that the TM dental implants performed similarly to the conventional threaded implants in an experimentally induced periimplantitis environment and did not exhibit bacterial infection.

5 References

1. Brånemark PI, Hansson BO, Adell R, Breine U, Lindström J, Hallén O, Öhman A. Scand J Plast Reconstr Surg. 1977;111 (Suppl 16):1-132.
2. Kim D, Huja S, Larsen P, et al. Conference Proceeding of European Association for Osseointegration. Glasgow, UK, 2010
3. Boby JD, Stackpool G, Hacking SA et al. J Bone Joint Surg Br. 1999; 81(5):907-914.

Note: Trabecular Metal™ is a trademark of Zimmer, Inc.